

# A Unique Failure Mechanism of a Distal Radius Fracture Fixed with Volar Plating

## A Case Report

William Min, M.D., M.S., M.B.A., Kevin Kaplan, M.D., Ryan Miyamoto, M.D., and Nirmal C. Tejwani, M.D.

### Abstract

*Various treatment options exist for distal radius fractures, and the complications associated with operative and nonoperative management are well documented in the literature. While surgical management with the use of various buttress and locked plating constructs has gained popularity, the long-term outcomes of these plating techniques have not yet significantly demonstrated improved outcomes, as compared to adequately reduced nonoperative measures. Furthermore, this operative technique can be associated with failures and complications. We present a case report of one volar-plate construct requiring revision, secondary to loss of fracture reduction, with no evidence of implant loosening or failure. A literature review on the complications associated with these plate constructs is also presented.*

Distal radius fractures are one of the most common injuries encountered by the orthopaedic surgeon. While a majority of these fractures are treated nonoperatively, surgical management with the use of various buttress and locked plating constructs has become popular. Although the long-term outcomes of these plating techniques have not yet significantly demonstrated improved outcomes, as compared to adequately reduced nonoperative measures,

William Min, M.D., M.S., M.B.A., is a Chief Resident; Kevin Kaplan, M.D., was an Administrative Chief Resident; and Ryan Miyamoto, M.D., was a Chief Resident, Department of Orthopaedic Surgery, NYU Hospital for Joint Diseases. Nirmal C. Tejwani, M.D., is an Associate Professor of Orthopaedic Surgery, New York University School of Medicine, and an Attending in the Division of Trauma Surgery, Department of Orthopaedic Surgery, NYU Hospital for Joint Diseases, NYU Langone Medical Center, New York New York.

*Correspondence:* Nirmal C. Tejwani, M.D., Department of Orthopaedic Surgery, NYU Hospital for Joint Diseases, 301 East 17th Street, New York, New York; nirmal.tejwani@nyumc.org.

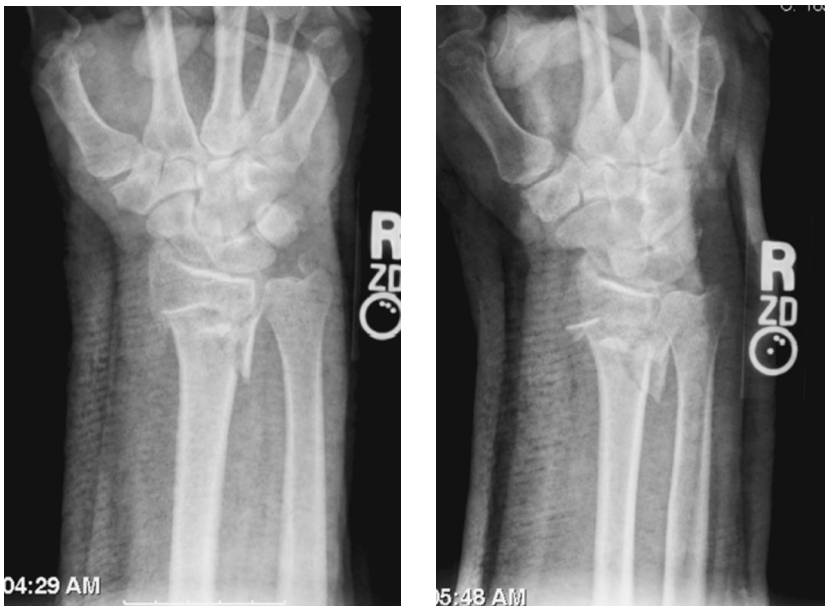surgery does serve a role in certain patient populations. However, this operative technique can be associated with failures and complications. We present a case report of one volar-plate construct requiring revision, secondary to loss of fracture reduction, with no evidence of implant loosening or failure. To our knowledge, this failure mechanism has not been reported before in the English literature.

### Case Report

The patient is a 56-year-old right-hand dominant male, with a social history significant for smoking (amount not specified), who sustained a right distal radius fracture after a mechanical fall (Fig. 1). The patient was examined in the emergency department, where a neurovascularly intact right distal radius fracture was noted. He initially underwent closed reduction that subsequently collapsed on follow-up radiographs. The patient was indicated for an open reduction internal fixation (ORIF) of the fracture one and a half weeks status post fall. The fracture was fixed using a volar locking plate (Hand Innovation Plate, Hand Innovations LLC, Miami, Florida) (Fig. 2).

The fracture reduction was maintained at 2 weeks. The patient was lost to follow-up until 3 months later, when he presented complaining of pain over the distal ulna, in addition to a clicking and “popping” in his affected wrist. The patient’s injury remained neurovascularly intact, but radiographic studies revealed distal radioulnar joint separation, with loss of radial height along the ulnar aspect (Fig. 3). Elbow imaging did not reveal any abnormalities. The distal radius fracture appeared healed. No loosening of any of the screws or evidence of a plate failure was noted on radiographs. At this time, the patient was indicated for revision of his initial operative fixation.

Intraoperatively, the fracture was well healed, and the loss of reduction was noted predominantly along the ulnar aspect of the distal radius. The distal screws were removed, and the



**Figure 1** Initial injury.

proximal screws were loosened, noting that none of them had come loose. An osteoclysis was performed and the plate was readjusted along the proximal and distal extent. After a reduction was performed, the original plate was reinstalled with tightening of the proximal screws and insertion of distal locking screws. Postoperative and follow-up examinations revealed maintenance of the reduction (Fig. 4).

## Discussion

The use of current plating technologies and constructs to operatively fixate distal radius fractures is gaining in popularity. With increasing numbers of orthopaedic surgeons adopting this technique, the learning curve should become more manageable, with complications steadily declining. Orbay and Fernandez discussed the use of volar fixation for dorsally displaced distal radius fractures.<sup>1</sup> In their study, a consecutive series of 29 patients with 31 dorsally displaced, unstable distal radial fractures were treated operatively with a fixed-angle internal fixation device. At a minimal follow-up time of 12 months, the fractures had healed with highly satisfactory radiographic and functional results.

In our case, we felt that the loss of reduction was a function of the comminution of the fracture. Despite the

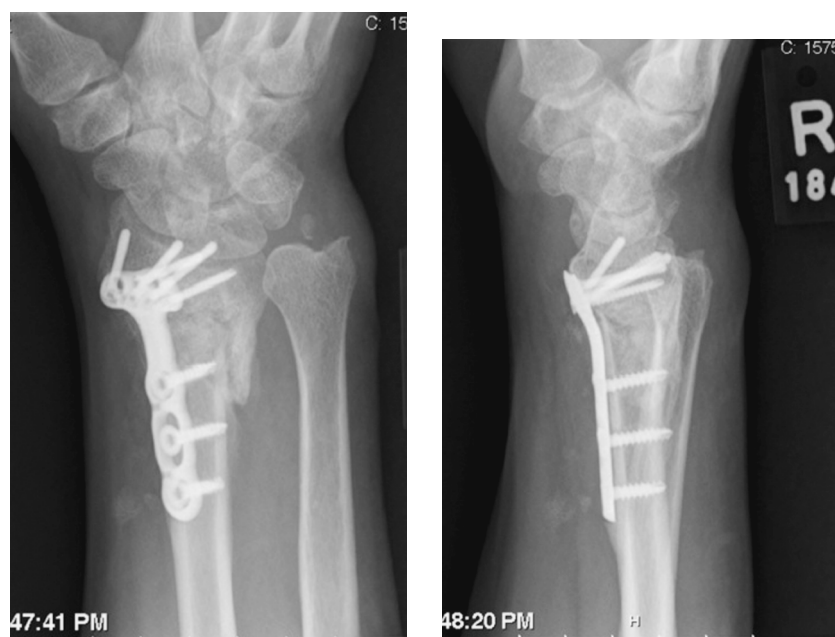
fact that the fracture was spanned with a locking plate assembly, it collapsed. This illustrates the need for additional fixation or bone grafting when spanning longer segments. Similar fixation failures, despite adequate fixation spanning, are also noted with internal fixation of proximal tibial fractures.<sup>2,3</sup>

Rozental and Blazar<sup>4</sup> reviewed their patients who had received internal fixation using volar plates for dorsally displaced, comminuted distal radius fractures. In a series of 41 patients, they found 9 with postoperative complications. There were four instances of loss of reduction with fracture collapse, three patients who required hardware removal for tendon irritation, one patient who developed a wound dehiscence, and one patient who had metacarpophalangeal joint stiffness. They concluded that patients with unstable, dorsally displaced fractures of the distal radius treated with volar fixed-angle devices have good or excellent functional outcomes, despite a high complication rate. When compared with previous reports on dorsal plating, volar plates appear to have a higher incidence of fracture collapse, but a lower rate of hardware-related complications. Complications unrelated to implant failure included one case of wound dehiscence in a patient who initially suffered severe burns.

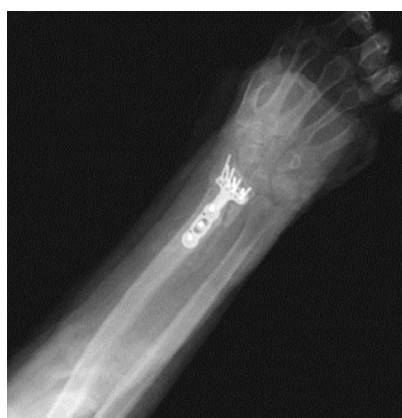A study by Arora and colleagues<sup>5</sup> examined the potential surgical risks and the observed complications of operative fixation of distal radius fractures. Over a mean 15-month period, 112 consecutive patients treated for an unstable dorsal dislocated distal radius fracture using the palmar locking-plate system were assessed. The functional results were compared with the uninjured contralateral side. From their study, favorable indications for palmar locking plate osteosynthesis are A2, A3, C1, and C2 fractures with large distal fracture fragments. In these cases, additional bone



**Figure 2** DePuy Hand Innovation Distal Radius Plate.



**Figure 3** Three weeks status post open reduction and internal fixation surgery.



**Figure 4** Revision and revised reduction.

grafting was not needed.

Between 1997 and 2001, Elsaidi and coworkers<sup>6</sup> examined 58 patients receiving dorsal plating for comminuted distal radius fractures. In eight of these patients, subsequent collapse led to palmar flexion deformity, loss of rotation, and hardware prominence. In retrospectively reviewing this subgroup's range of motion, radiographic volar tilt, and complications, including tenosynovitis and extensor tendon rupture, the investigators found the following: 1. with both palmar and dorsal comminution of distal radius fractures, dorsal plating may not prevent palmar cortex collapse; 2. deformity of the distal radius fragment causes palmar displacement of the radius relative to the intact ulna; 3. resultant incongruity at the distal radioulnar joint causes a significant loss of supination; and 4. palmar distal radius displacement leads to dorsal hardware prominence and may contribute to tenosynovitis and attritional extensor tendon ruptures.

## Conclusion

Careful preoperative planning and consideration of the patient's overall status (occupation, hand dominance, and medical comorbidities) must be considered prior to operative management of a distal radius fracture. While these surgeries have shown considerable success, a note of caution should be considered based upon the complications noted both in the literature and in this case report.

## Disclosure Statement

None of the authors have a financial or proprietary interest in the subject matter or materials discussed, including, but not limited to, employment, consultancies, stock ownership, honoraria, and paid expert testimony.

## References

1. Orbay JL, Fernandez DL. Volar fixation for dorsally displaced fractures of the distal radius: a preliminary report. *J Hand Surg Am.* 2002;27(2):205-15.
2. Bono CM, Levine RG, Rao JP, Behrens FF. Nonarticular proximal tibia fractures: treatment options and decision making. *J Am Acad Orthop Surg.* 2001;9(3):176-86.
3. Tejwani NC, Hak DJ, Finkemeier CG, Wolinsky PR. High-energy proximal tibial fractures: treatment options and decision making. *Insr Course Lect.* 2006. 55:367-79.
4. Rozental TD, Blazar PE. Functional outcome and complications after volar plating for dorsally displaced, unstable fractures of the distal radius. *J Hand Surg Am.* 2006;31(3):356-65.
5. Arora R, Lutz M, Zimmermann R, et al. Limits of palm ar locking-plate osteosynthesis of unstable distal radius fractures. *Handchir Mikrochir Plast Chir.* 2007;39(1):34-41.
6. Elsaidi GA, Deal N, Smith BP, Ruch DS. Volar collapse after dorsal plating of comminuted distal radius fractures. *Am J Orthop.* 2007;36(5):269-72.